

Sarcoidosis in an Australian Aborigine and a Torres Strait Islander

Robert J MacGinley, Roger KA Allen

Department of Thoracic Medicine, The Prince Charles Hospital, Brisbane, Australia

Abstract. *Background and aim:* This is the second case report of sarcoidosis in an Australian Aborigine and the first in a Torres Strait Islander. The Australian Aborigine had atypical superior mediastinal lymphadenopathy and uveitis while the Torres Strait Islander had persistent pulmonary disease requiring oral corticosteroids. *Conclusions:* Indigenous Australians appear to be rarely affected by sarcoidosis. However, it is common in people of Celtic origin. The presence of a European (Celtic) ancestor in the family tree of both individuals suggests that yet unknown genetic factors may be important in the pathogenesis of their disease.

Key Words. Sarcoidosis. Australian Aborigine. Torres Strait Islander.

Introduction

Sarcoidosis although common and characteristically severe in most black races, especially Afro-Americans, is uncommon in Australian Aborigines and has not been described in Torres Strait Islanders. It has only been described in one Australian Aborigine [1] and from personal communication with Australian physicians involved in aboriginal health, it appears to be distinctly uncommon and this explains why there are no other reports in the literature. Additionally we are currently conducting the first prospective data base on sarcoidosis in Australians and we are aiming to establish a worldwide data-base for sarcoidosis [2-5]. We present two case reports; one of an Australian Aborigine and the other of a Torres Strait Islander.

Case Report 1

A 49-year-old woman who identified herself as "Aboriginal", presented to her local doctor in Coffs Harbour in March 1992 with exertional retrosternal chest pain, three months of mild exertional dyspnoea, lethargy and arthralgias in her left elbow and shoulder. She had smoked for eleven pack years, was a moderate drinker and a non-insulin dependent diabetic for 18 years.

She was of Aboriginal inheritance but with an Irish maternal great-grandfather. All her other ancestors were from a local Aboriginal tribe (Bundjalung). She had never contracted tuberculosis.

Her chest radiograph (Fig. 1) showed a superior mediastinal mass which on mediastinal biopsy revealed lymph nodes with non-caseating granulomas with no organism subsequently cultured (Stage I disease). An exercise stress testing produced pain and ST changes within two minutes, consistent with ischaemic heart disease. She was then referred to our Institution for further investigation in April 1992. Her physical examination revealed coarse bilateral basal crackles and right basal wheeze with no superior vena cava obstruction.

A chest CT scan showed a right paratracheal mass extending posteriorly to the superior vena cava and to the carina anteriorly, with a large subcarinal lymph node mass anterolateral to the aortic arch and also in the aortopulmonary window. There was mild interstitial shadowing in the right lower lobe. Abdominal CT was normal. A ⁶⁷Ga scan (total body) showed markedly enhanced radionuclide activity in the superior and posterior mediastinum but no abnormal lung parenchymal, salivary or abdominal uptake.

Her erythrocyte sedimentation rate (ESR) was 44 mm/hr, full blood examination normal, serum electrolytes, serum and 24 hr urinary calcium, and liver function tests also normal. Her serum angiotensin-converting enzyme (ACE) was moderately elevated at 290 u/l (RR 30-170 u/l) and there was a mild polyclonal gammopathy. No pathogens (including tuberculosis or fungi) were isolated on subsequent culture of bronchial washings or lavage.

Received: 6 June 1995

Accepted after revision: 28 June 1996

Correspondence: R.K.A. Allen, M.D.

Department of Thoracic Medicine, The Prince Charles Hospital,
Rode Road, Chermside, Brisbane, Australia 4032

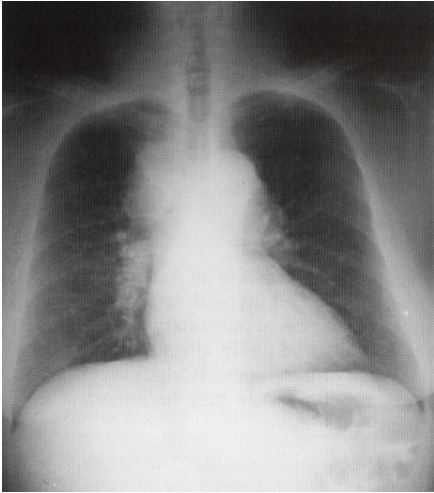


Fig 1. Chest radiograph of patient 1 showing mediastinal lymphadenopathy consistent with Stage I sarcoidosis.

Respiratory function tests (flow volume loops, lung volumes and carbon monoxide uptake, predicted values standardised for race) showed a restrictive ventilatory defect; FEV₁ 2.04l/VC 2.251 (% predicted 104%/88.8% respectively) with reduced D_{LCO}(67.9% of predicted) but normal K_{CO} (89.3% of predicted), consistent with reduced lung volumes. Although she had no visual symptoms, ophthalmological examination showed bilateral anterior uveitis, bilateral vitritis, bilateral vasculitis. A fluorescein angiography showed bilateral retinitis. Her Schimer's test was normal. An ophthalmologist, who has extensive experience in ophthalmic sarcoidosis, considered these features characteristic of sarcoidosis and not of diabetes.

A resting 12-lead ECG showed low voltages and inferolateral T-wave flattening and inversion. A 12-lead exercise ECG showed only minor upsloping ST-segment depression in the inferolateral leads. An exercise thallium scan showed a small apical perfusion abnormality but with normal activity in the remainder of the myocardium. Following thallium reinjection at rest, the small perfusion defect was no longer apparent. These features were consistent with ischaemic heart disease rather than

cardiac sarcoidosis.

She was continued on sorbide nitrate 10mg tds which controlled her angina and commenced on prednisolone eye drops. Her anterior segment responded well without the need for oral steroids.

Case Report 2

A 56-year-old man who identified himself as a Torres Strait Islander living in Brisbane presented to our Institution in September 1993 with six months of increasing exertional dyspnoea, night sweats, dry cough and 30 kg weight loss. Apart from gritty eyes he had no other symptoms typical of sarcoidosis. He had a ten-year history of ischaemic heart disease culminating in coronary artery bypass grafting in 1991 for triple vessel disease. He also had non-insulin dependent diabetes mellitus, hypertension, lifelong smoking, obesity, Type IIb hyperlipidaemia and emphysema.

The patient's parents were Torres Strait Islanders who lived in the Torres Straits and although his paternal grandfather was a Torres Strait Islander, his paternal grandmother was Irish, his maternal grandfather English and his maternal grandmother was Maori.

On admission in September 1993, he was unwell, dyspnoeic at rest, febrile (37.4°C) with fine expiratory crackles in both midzones. There was a 3 cm mobile node in his axilla and he had mild xerophthalmia. His physical examination was otherwise normal.

Investigations showed a markedly elevated serum ACE 374 u/l (RR 30-170 u/l), an elevated 24 hr urinary calcium (18.1 mmol/24hrs) and a transbronchial biopsy showing non-caseating granulomas with no pathogens cultured subsequently. His chest radiograph (Fig. 2) showed bilateral interstitial and alveolar shadows coalescing in both midzones with right paratracheal and right hilar lymphadenopathy (Stage II disease). A chest CT showed honeycombing of the upper zones with some fibrosis, right middle lobe alveolar and interstitial shadowing and bilateral basal bronchiectasis with mediastinal lymphadenopathy involving right paraoesophageal, pretracheal and subcarinal regions (Stage II disease). A ⁶⁷Ga scan (total body) showed a diffuse uptake in the lungs but surprisingly no increase in hilar and mediastinal uptake. Although his full blood examination and electrolytes were normal, his ESR was moderately elevated (40 mm/hr). Respiratory function tests consistently showed a mixed ventilatory defect; FEV₁ 1.64l/VC 2.451 (58%/63% of predicted respectively) with a reduced D_{LCO} 11.65 ml/min/mmHg (predicted 24.16) and reduced K_{CO} 2.97 ml/min/mmHg/l (predicted 4.25). After four months of prednisolone his lung function improved (FEV₁ 2.02l/VC 3.081) with no improvement in carbon monoxide uptake.

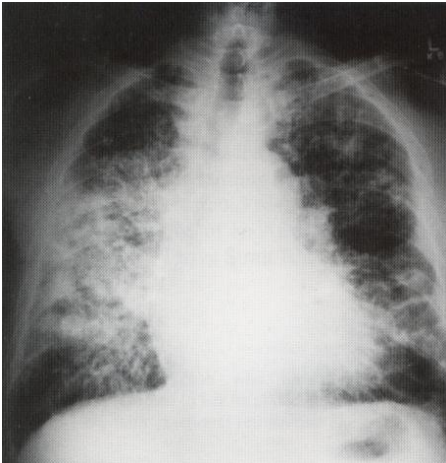


Fig 2. Chest radiograph of patient 2 showing parenchymal lung changes and predominantly right hilar adenopathy consistent with Stage II sarcoidosis.

In May 1994, cardiac sarcoidosis was virtually excluded by normal results on echocardiography, resting gated heart pool scan, gated cardiac Magnetic Resonance Image (MRI) (with gadolinium) and an endomyocardial biopsy of the right ventricle. A resting 12-lead ECG showed atrial fibrillation and T wave inversion laterally, consistent with ischaemic heart disease. A Holter monitor showed only atrial fibrillation/flutter. Biopsy of a keloid-like skin lesion on his arm showed granulomata consistent with sarcoidosis.

The patient was treated with oral prednisolone (initially 40 mg/day) throughout 1993 and 1994 for dyspnoea and to prevent declining respiratory function.

Discussion

Both anecdotes and published reports suggest that sarcoidosis is uncommon in Australian Aborigines and Torres Strait Islanders although mycobacterial disease, both typical and atypical is relatively common [6]. There is one published report of an Australian Aborigine with sarcoidosis [1] and no reports of sarcoidosis in Torres Strait

Islanders. This report by Webling in 1975 was of a 42-year-old “full blooded” Aboriginal (heritage not further described in the case report), who presented with a productive cough, cervical lymphadenopathy, bilateral basal crackles and a chest radiograph showing enlarged hilar glands with some linear and small nodular shadows in the perihilar areas. A biopsy of a palpable cervical gland showed the typical appearances of sarcoid-like granulomata with some haemosiderin deposits. Culture was negative for mycobacterium. The radiographic changes and lymphadenopathy resolved spontaneously within two years.

Both our cases had some European (predominantly Irish) forebears which may have been a significant factor in the pathogenesis of their disease. Both patients had some atypical features. The first patient presented with an upper mediastinal mass which was atypical for sarcoidosis and more like a lymphoma. She had two types of chest pain; one due to ischaemic heart disease and the other due to mediastinal adenopathy. From our retrospective studies and prospective studies of over 400 patients with sarcoidosis, approximately 20% present with retrosternal chest pain from mediastinal nodes or pleuritic pain due to pleural involvement with sarcoidosis [2]. Although she had an elevated serum ACE, histological confirmation was performed to exclude lymphoma and mediastinal seminoma, both reported to elevate serum ACE [7,8].

The second patient had severe stage II disease with a protracted course with cardiac sarcoidosis also requiring exclusion in the setting of coexisting ischaemic heart disease. The role of gated cardiac MRI is still being evaluated for the diagnosis of cardiac sarcoidosis in our Institution [9]. The difficulty in effectively excluding cardiac sarcoidosis in both these patients who also had coexisting ischaemic heart disease, presented a significant clinical problem. His cutaneous sarcoidosis has not been an ongoing problem.

The first patient had asymptomatic ophthalmic sarcoidosis which may have gone undiagnosed without a formal eye assessment. The spontaneous regression of her mediastinal lymphadenopathy was followed by an unexpectedly rapid improvement in her eye disease which was treated only with topical corticosteroids on advice from our ophthalmologist.

We suspect that the onset of sarcoidosis in both patients may be due to an unknown genetic factor common in Europeans. If sarcoidosis can be proven to be as rare in the Australian Aboriginal population as we believe, studies of the genetics of sarcoidosis in this group could cast light on the pathogenesis of this disease.

Acknowledgements

Dr P. Nolan, Thoracic Physician, for supplying clinical details in the second case.

References

1. Webling D D'A: Sarcoidosis in an Australian Aboriginal. *Med J Aum* 1978; 1: 169-170.
2. Allen RKA et al: A prospective study of Sarcoidosis in Australian Patients. *Saicooidosis* 1994; 11 (suppl 1): 252-254.
3. Allen RKA et al: Neurological involvement in Sarcoidosis: A prospective Australian study. Abstract p/154 from Joint Meeting of World Association of Sarcoidosis and Other Granulomatous Disorders and British Society for Allergy and Clinical Immunology 15-20 October 1995, London.
4. Allen RKA et al: Male predominance in 205 Australian patients with Sarcoidosis. *Sarcoidosis* 1992; 9 (suppl 1): 269-270.
5. Allen RKA et al: A proposal to establish a world-wide database. *Sarcoidosis* 1992; 9 (suppl 1): 267-268.
6. Krause VL, Britton WJ: Tuberculosis in the Tropics. *Med J Aust* 1993; 159: 412-415.
7. Saint-Andre JP: Angiotensin-1 converting enzyme in germinomas. *Hum Pathol* 1988; 19:208-213.
8. Romer FK: Clinical and biochemical aspects of sarcoidosis with special reference to angiotensin-converting enzyme (ACE). *Acta Med Scand* 1984; 690 (suppl): 1-96.
9. Allen RKA et al: A prospective study of cardiac Sarcoidosis in an Australian population. Abstract p/153 from Joint Meeting of World Association of Sarcoidosis and Other Granulomatous Disorders and British Society for Allergy and Clinical Immunology 15-20 October 1995. London.